

Supplementary data

Laparoscopic Management of Perforated Peptic Ulcer: Multicenter Experience

Abdallah Mohamed Taha^{a*}, Mahmoud Abdelhameid^a, Ahmed Saada^a, Ahmad Maklad^b, Ramy Hassan^c, Mohamed Abdelshafy^a

¹Department of General Surgery, Faculty of Medicine, South Valley University, Qena, Egypt.

²Department of General Surgery, Faculty of Medicine, Suez University, Egypt.

³Department of General surgery, Faculty of Medicine, Assuit University, Assuit, Egypt.

DOI: 10.21608/svuijm.2023.194638.1530

*Correspondence: abdallahsurgery@med.svu.edu.eg

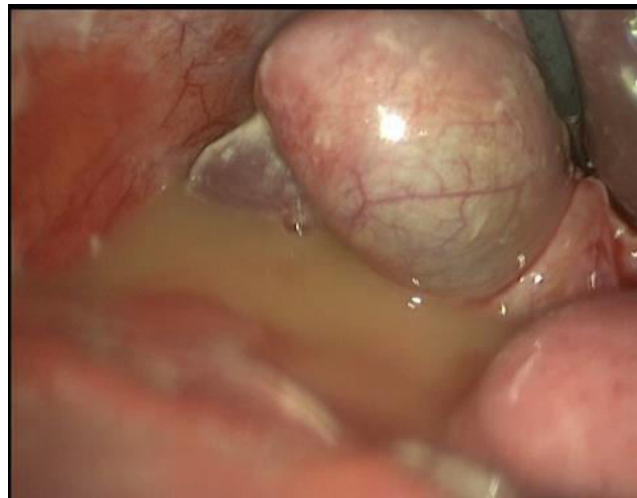

Fig.1. Turbid fluid collection in perforated peptic ulcer, laparoscopic approach.

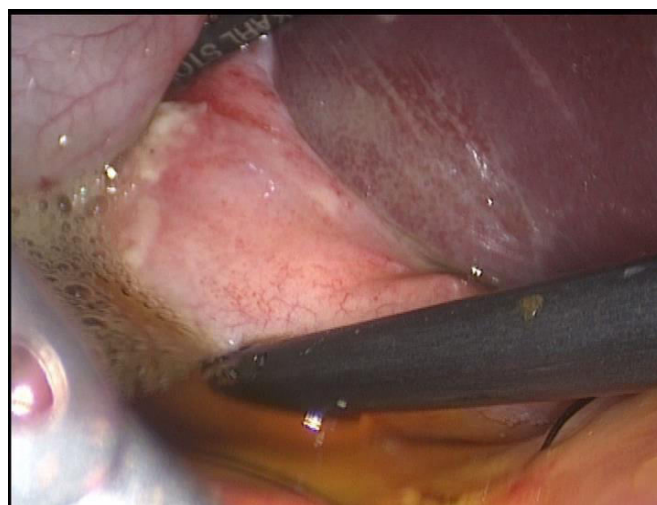


Fig.2. Irrigation suction peritoneal lavage, laparoscopic approach.

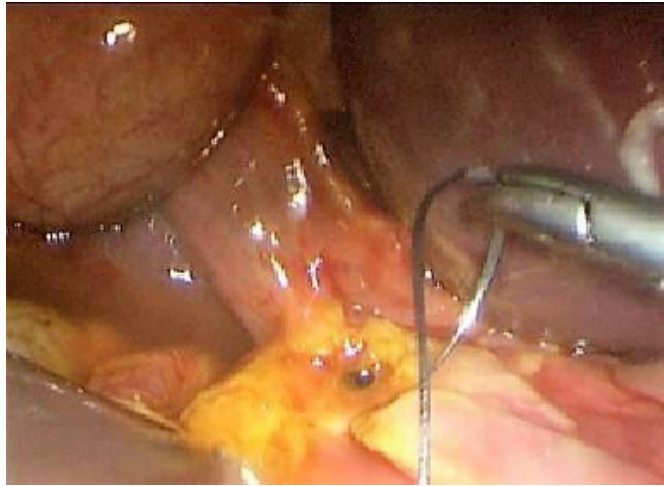


Fig.3. Laparoscopic intra-corporeal suturing of perforated peptic ulcer.

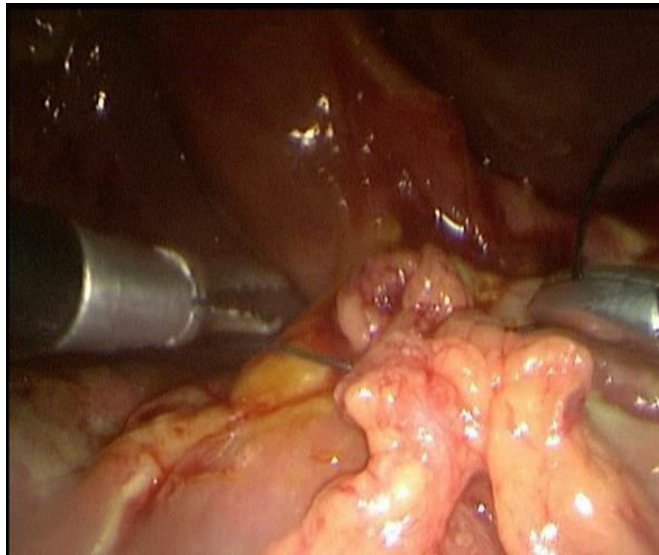


Fig.4. Laparoscopic picture showing completed repair of perforated duodenal ulcer with pedicled omental flap.

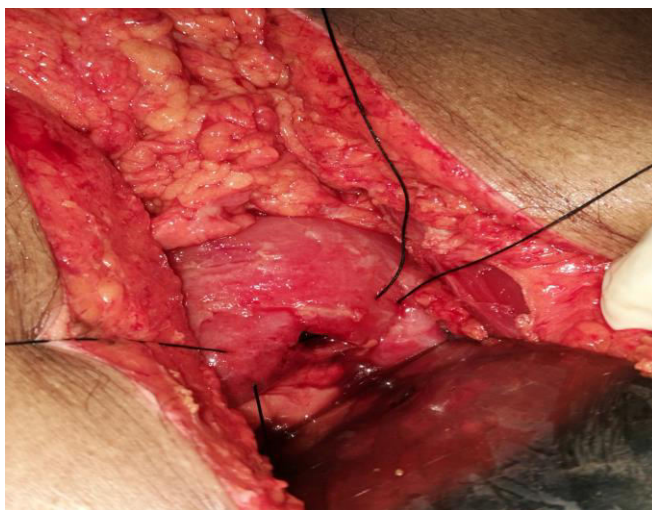


Fig. 5. Site of perforated duodenal ulcer, open approach.

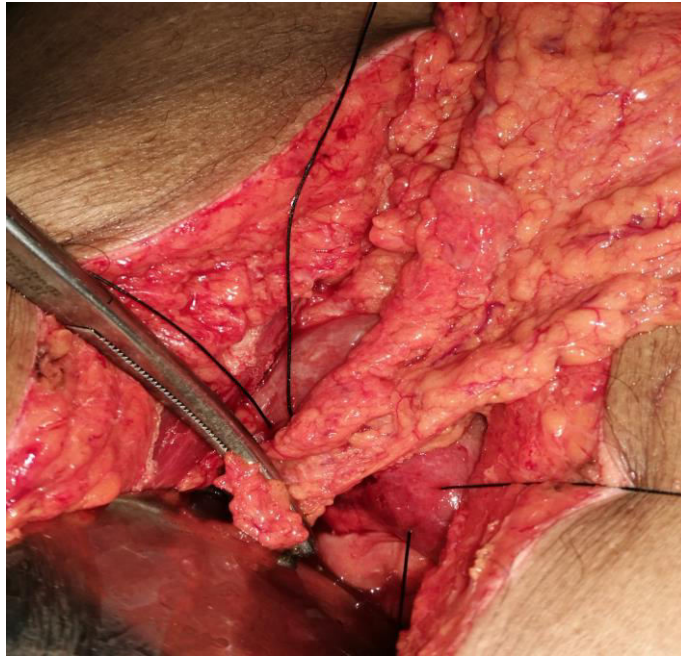


Fig.6. Prepared pedicled omental flap for closure of perforated duodenal ulcer, open approach.

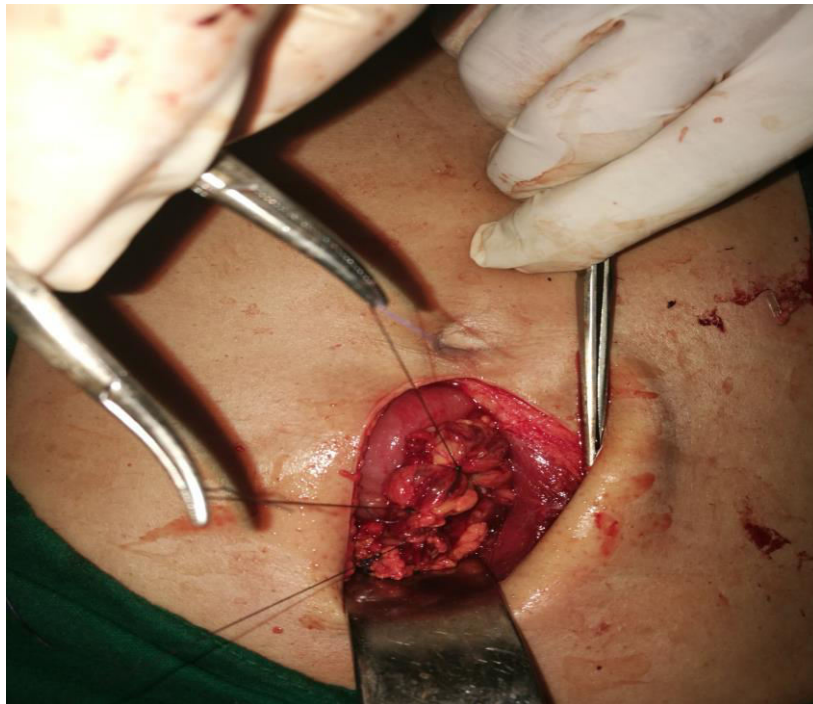


Fig. 7. Complete closure of perforated duodenal ulcer with pedicled omental flap, open approach.