

Neurological Diseases: Cause and Effect in the Era of COVID-19**Islam Elmalky^a, Eptehal Dongol^b, Hazem Abdel khalek^c**^aDepartment of Neurology, Faculty of Medicine, South Valley University, Qena, Egypt.^bDepartment of Chest Disease, Faculty of Medicine, South Valley University, Qena, Egypt.^cDepartment of Neuropsychiatry, Faculty of Medicine, Tanta University, Tanta, Egypt.**Abstract**

Background: SARS-CoV-2 new infectious disease was first reported in Wuhan, China in December 2019. Thereafter, it has extensively spread causing global pandemic. It was named as corona virus disease 2019 (COVID-19) by WHO in February 2020. Other than the well described COVID-19 respiratory and cardiac manifestations, the neurological manifestations are not that uncommon.

Objectives: In this review, we are trying to shed light on this pandemic disease and its neurological presentation, which might enable neurologists to pick up and promptly deal with such cases. The COVID-19 neurological presentation can include many diverse symptoms and rapid clinical deterioration can be related to development of neurological affection. Moreover, the patients with already neurological diseases, when affected by the COVID-19 showed worse prognosis.

Conclusion: Enhanced research is needed to illustrate and explain and hence development and tailoring adjusted treatment for the neurological manifestation for better management of such cases to improve the outcome.

Key words: COVID-19, Neurological diseases, Corona Virus, Peripheral Nervous System, Central Nervous System.

Introduction

Coronavirus disease (COVID-19) was first discovered in December 2019 in Wuhan, China and has rapidly transmitted to whole world. The World Health Organization (WHO) has declared COVID-19 as a pandemic on 11 March 2020.

The typical presentation of COVID-19 can range from mild to severe respiratory illness. The most common symptoms that have been reported so far are fever, cough, and shortness of breath. The elderly population, especially those with comorbid conditions such as chronic bronchitis, emphysema, heart failure, or diabetes, are more likely to develop serious illness (Guan et al., 2020).

Neurological manifestations of COVID-19 were reported considerably. Among the early reports was that of Mao et al in last April. 36.4% of their study subjects had nervous system symptoms. The most common complaints were dizziness (16%) and headache (13.1%). Regarding the cranial nerve affection symptoms, the most common complaints were hypogeusia (5.6%) and hyposmia (5.1%). Moreover, they found that nervous system symptoms were significantly more common in severe cases as compared with non-severe cases. Cerebrovascular stroke cases represented (5.7%) (Mao et al., 2020). The pathogenesis is still not fully understood.

Some of the neurological symptoms may be presented before the respiratory symptoms, and this should be highlighted to the neurologists. They should consider Severe Acute Respiratory Syndrome Corona Virus 2 (SARS-CoV-2) infection as a differential diagnosis to avoid delayed diagnosis or misdiagnosis and to ensure prevention of transmission. Rapid clinical deterioration could be related to a neurological event such as stroke, which would contribute to the disease high mortality rate. However, many preprint case reports and surveys may not give a true image about the neurological problems in COVID-19 era. Additionally, coincidental occurrence of neurological diseases is likely.

In this review, we aim to highlight the neurological complications of COVID-19, try to explain them and clarify the potential effect of COVID-19 on the neurological diseases and their treatment.

Structure of SARS-CoV-2

SARS-CoV-2 belongs to the broad family of coronaviruses. It is the seventh known CoV (corona viruses) that can infect humans (Chanet al., 2020). It is an enveloped, positive sense, single-stranded RNA (+ssRNA) virus with a diameter of approximately 60–140 nm. The viral envelope is formed of a lipid bilayer with four structural proteins. They are known as S (spike), E (envelope), M (membrane), and

N(nucleocapsid) proteins (Chanet al., 2020). Interaction between the spike protein (S) and host cell receptor is essential for virulence and infectivity. SARS-CoV-2 is a member of the genus Betacoronavirus (β CoV). This genus also includes SARS-CoV (the causative agent of the SARS global outbreak in 2003) and Middle East respiratory syndrome coronavirus (MERS-CoV). SARS-CoV-2 has shown 82% identity with SARS-CoV in the genomic sequence analyses. A mutation in the spike protein could be the culprit for the recent introduction of SARS-CoV-2 into the human population (Chanet al., 2020).

COVID-19 and CNS (central Nervous System) complications

Multiple studies described the non-specific neurological symptoms affecting COVID-19 patients, such as headache and encephalopathy, which were affecting up to 40% of patients in some studies (AK et al., 2020, Mao et al., 2020). These non-specific symptoms could occur with any infection causing sepsis, and this may be an indirect effect on CNS. In a report of Chinese Center for Disease Control and Prevention analyzing 44,500 confirmed COVID-19 patients, 14% of the patients with neurological manifestations had severe form of the disease with significant dyspnea and hypoxia, while 5% of them had respiratory failure, shock (septic or cardiac), or multi-organ dysfunction (AK et al., 2020,

Tanget al., 2020). These non-specific neurological manifestations can be explained through many mechanisms (**Figure.I**). First, when the infection reaches the alveoli of the lungs, this induces inflammatory reaction and exudate that disturb the gas exchange process leading to hypoxia and anaerobic metabolism in the mitochondria of brain cells (**Guo et al., 2020**). Second, neurological symptoms like encephalopathy and stroke could occur subsequent to cardiac injury, which is caused by direct and indirect cardiotoxicity secondary to excessive systemic pro-inflammatory stimulation (cytokine storm), hypercoagulability, or direct myocardial invasion (**Dehisset al., 2015**). Cytokine storm can occur after invasion of the lung epithelium. SARS-CoV-2 directly infects T cells and macrophages, contributing to lymphopenia with reduced CD4+ and CD8+ cell counts and dysregulation of the normal adaptive immune responses. Excessive production of pro-inflammatory cytokines, including different interleukins (IL-1 α , IL-6, IL-10) and tumor necrosis factor-alpha (TNF1 α), with subsequent downregulation of anti-inflammatory cytokines such as interferon gamma (IFN- γ), are thought to contribute to the excessive inflammation and activation of pro-apoptotic pathways (**Mehta et al., 2020**). This cytokine storm may lead to microvascular inflammation and microthrombi formation in different tissues.

The high levels of D-dimer and low platelets are clues of this process. Yin et al reported a case of encephalopathy with altered consciousness and irritability and high protein. However, CSF analysis was negative for SARS-CoV-2. This may be due to the indirect effect (**Yin et al., 2020**).

A confirmed COVID-19 case of encephalitis was reported in Wuhan, china. This case showed also negative CSF analysis for SARS-CoV-2. The neurological presentation was 13 days after fever, sore throat and myalgia, indicating to the theory of immunological reaction (**Ye et al., 2020**). Regarding the direct viral invasion, the hematological spread theory is considered. It postulates that the virus binds to ACE2 (Angiotensin Converting Enzyme 2) receptor on endothelial cells during the viremia stage, especially when there is a sluggish flow in the microcirculation. This enables the spread to the brain tissue as formerly described with SARS-CoV (**Baiget al., 2020**). The presence of these receptors in the olfactory epithelium may also allow the direct invasion through the cribriform plate. An autopsy study reported that edema has been detected in brain tissue of COVID-19 patients (**Xu et al., 2020**). Also, increasing evidence shows that CoVs may first invade peripheral nerve terminals, and then gain access to the CNS via a synapse connected route (**Liet al., 2012**). The trans-synaptic transfer has been well documented with other

CoV_s(Liet al., 2012, Letkoet al., 2020).The nucleus of the solitary tract receives sensory information from the mechanoreceptors and

respiratory rate and type 1 respiratory failure, with low CO₂ levels (Turtle et al., 2020). The respiratory failure due to central cause is type 2 respiratory failure, with high CO₂ levels and

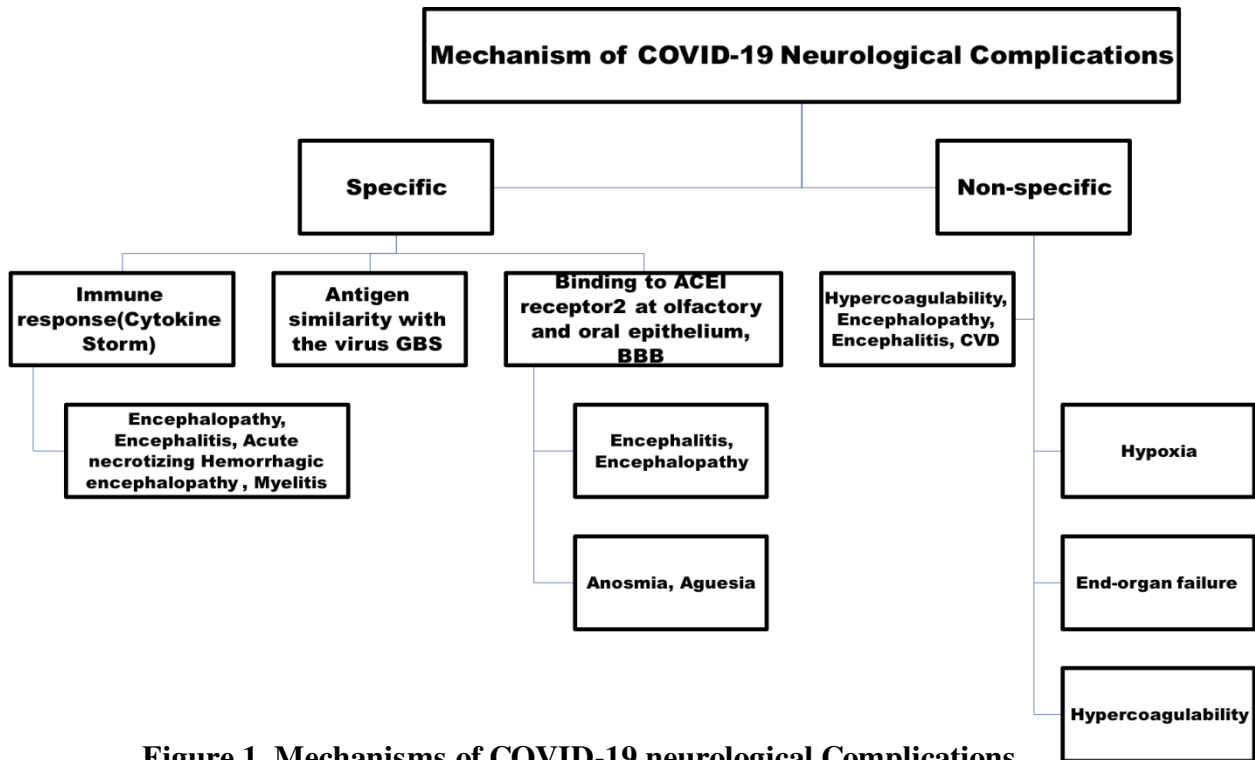


Figure 1. Mechanisms of COVID-19 neurological Complications

chemoreceptors in the lung and respiratory tracts, while the efferent fibers from the nucleus ambiguus and the nucleus of the solitary tract provide innervation to the airway smooth muscles, glands, and blood vessels(Kalia et al., 1980). These neuroanatomical connections may play a role in the dysfunction of the cardiorespiratory center in the brainstem. This theory was refused by Turtle et al who suggested that respiratory failure is a peripheral mechanism, not a central one. Their evidence was that the COVID-19 patients with ARDS (Acute respiratory distress Syndrome) had raised

low respiratory rate which was not the case in Chinese patients.

On March 4, 2020, Beijing Ditan Hospital reported for the first time a case of viral encephalitis caused by COVID-19. The researchers confirmed the presence of SARS-CoV-2 in the cerebrospinal fluid (CSF) by the genome sequencing. This finding ensured that the SARS-CoV-2 has the potential to cause a nervous system invasion(Xianget al., 2020).Encephalitis was reported in a patient with negative nasopharyngeal swap but positive CSF COVID-19 testing. This

support the theory of direct invasion. MRI, in this case, showed the typical finding of encephalitis in the form of restricted diffusion and fluid attenuated inversion recovery (FLAIR) hyperintense lesion at mesial part of temporal lobe with the presence of paranasal sinusitis (Moriguchi et al., 2020).

In view of the high prevalence of COVID-19, it is not that uncommon to coincide with the cerebrovascular disease (CVD). However, there is growing evidence that respiratory infection is an independent risk factor for ischemic stroke (Warren et al., 2018, Helms J. et al., 2020). Oxley et al reported five cases of large vessel occlusion in New York city, as the presenting symptoms for COVID-19 (Oxley et al., 2020). The initial symptoms were only cough, lethargy and chills. Fever as a symptom was reported only in one patient from those five. This raises the attention of the possibility of COVID-19 related neurological manifestations, such as stroke. In this case series, three patients of the five had no known risk factor of stroke, and most of them had high level of D-dimer. In another case series, Avula et al reported four cases of CVD. Three of them had high D-dimer and CRP (C-reactive protein) levels. All were elderly above 70 years and had multiple neurological risk factors. All of them presented by neurological symptoms before chest symptoms (Avula et al., 2020). This may confirm the theory of high inflammatory process leading to

hypercoagulability and stroke. Beyrouti et al also reported six COVID-19 cases with stroke, all of them had large vessel occlusion with high D-dimer and lupus anticoagulant (Beyrouti et al., 2020).

It should be kept in mind that social distancing, isolation, and reluctant presence to the hospital due to fear of infection may contribute to poor outcomes in most of stroke patients. Morelli et al reported that the number of stroke patients presented to the hospital were decreased in comparison to the number recorded at the same time of the last years in Italy (Morelli et al., 2020). Mao et al reported that the incidence of stroke in COVID-19 patients was 5%. This is considered relatively high and not coinciding with the reported data outside China, which raises questions about the ethnic variations and genetic predisposition of COVID-19 related neurological compromise (Mao et al., 2020).

One case of cerebral hemorrhage was reported in a Chinese study (Mao et al., 2020). This may be explained by the COVID-19 associated thrombocytopenia and blockage of ACE2 receptors, with subsequent blood pressure fluctuation. Brun et al reported small-vessel CNS vasculitis as a rare but silent complication of sedated patients with COVID-19 (Brunet et al., 2020).

Zhao et al reported a case of acute myelitis, that presented by fever only with no respiratory symptoms. The acute myelitis symptoms

occurred seven days later. However, the CSF analysis was not performed, so direct invasion of the spinal cord could not be confirmed. The possibility of immunological reaction against the spinal cord leading to myelitis was otherwise suspected, especially in view of the delayed occurrence (Zhao et al., 2020).

Acute necrotizing hemorrhagic encephalopathy (ANE) was diagnosed in a female patient aged more than fifty. Her symptoms progressed rapidly within 3 days. They mainly were fever, cough and mental deterioration (Poyiadjet et al., 2020). She had a positive nasal swab for SARS-CoV-19. The CSF testing for SARS-CoV-19 couldn't be performed, and there were no other viral or bacterial pathogens in the CSF analysis. The cause was suggested to be an immunological reaction or cytokine storm against brain tissue. Another similar case, but with an extensive involvement of the pons, medulla, striatum and the subcortical peri-rolandic regions was recorded without virus detection in CSF also (Wonget al., 2006). Karimiet al reported a COVID-19 female patient who presented with multiple attacks of seizures, fever and cough. She was confirmed by nasal swab test, but had negative CSF analysis (Karimiet al., 2020). This is also indicating that immunological reaction may be implicated in such symptoms. Previous studies reported that TNF α , IL-6 cytokines and C3 of the complement system could cause neuronal

hyper-excitability via activation of the glutamate receptors and play a role in the seizure event (Libbey et al., 2011).

COVID-19 and Neuromuscular System

Across sectional study conducted by Tang et al showed that fatigue and myalgia were the most common musculoskeletal symptoms in the studied 20,626 COVID-19 patients. They found also that creatine kinase (CK) and CK-MB levels were high in 13.87%, and 16.76% respectively, indicating skeletal muscle injury that was confirmed by lactate dehydrogenase (LDH) levels measurement. Furthermore, CK and LDH were significantly higher in patients with severe disease when compared with those with mild or moderate disease (Tang et al., 2020). This could be explained by the binding of the virus to ACE2 receptors or the effect of the pro-inflammatory cytokines. However, this needs more future post-mortem examination studies. These results may indicate SARS-CoV-2 testing for patients with myalgia.

What comes to most neurologists' mind initially is Guillain-Barré syndrome (GBS), which follows viral infections (e.g., Influenza, H1N1, ZIKA, EBV, etc.). The rationale is that the molecular similarity exists between specific viral proteins and proteins on peripheral nerves (e.g., gangliosides) is leading to an attack against the myelin or axon of peripheral nerves. Chan M. et al., 2020 reported two COVID-19 cases with GBS in

New York. The symptoms of GBS started one to two weeks after fever and respiratory symptoms. The patients received intravenous immune globulin (IVIg) and became clinically free. Also, **Ebrahimzadeh et al., 2020** reported two cases of GBS in Iran. The symptoms of GBS started 10 to 18 days after COVID-19 presentation. One patient was treated by IVIg. Toscano et al 2020 reported five COVID-19 Italian cases of GBS with the symptom's onset was five to ten days after the disease presentation. The CSF testing for SARS-CoV-2 was negative. Two patients had the axonal type of GBS (bad outcome) and three had the demyelinating type (good outcome). These patients were treated mainly by IVIg, plasma exchange was performed in one patient. Two patients had been mechanically ventilated at the end, while three patients had good outcome. Not surprisingly, patients with severe form of COVID-19 developed critically advanced myopathy or polyneuropathy. Weakness which is related to type 2 muscle fiber atrophy from disuse typically presented after one week in ill bedridden patients (**Toscano et al., 2020**). Therefore, it should be kept in mind that the use of non-depolarizing neuromuscular blocking agents in critically ill patients is a risk factor for occurrence of myopathy and polyneuropathy (**Torbic et al., 2019**).

Cranial Neuropathy in COVID-19

The American academy of otolaryngology-head and neck surgery has released a statement recently stating that anosmia and dysgeusia are significant symptoms associated with COVID-19 (**Kaye et al., 2020**). Smell and taste loss were reported to be experienced in COVID-19 patients 10 folds more than in influenza patients with profound degree of the loss. Most of patients improved within two weeks after the respiratory symptoms (**Giacomelli et al., 2020, Yan et al., 2020**).

Mao et al reported that the incidence of hypogeusia and hyposmia in COVID-19 patients was 5.6% and 5.1 % respectively (**Mao et al., 2020**). Other Chinese reports showed relatively similar incidence of nasal symptoms (4-5%) in COVID-19 patients (**Guan et al., 2020; Yin et al., 2020**). These results are so far from those were reported by the multicenter European study, which reported that smell and taste dysfunctions were found in up to 85.6% of the total COVID-19 patients (**Lechien et al., 2020**). This obvious variation may be explained by the well documented different genome for the same virus. Interestingly, mutations of surface proteins (spike-S-protein and nucleocapsid N-protein) which are responsible for virus entry into the cell and virus transcription respectively were found. Another explanation could be the diversity of ACE2 expression between Asian

and European populations (Cao Y. et al., 2020). Vaira et al., 2020 reported the first objective evaluation of the olfactory and taste functions. They reported that 73.6% of COVID-19 patients had one or two problems in the two functions (smell and taste). 9.1% of the patients had no other nasal symptoms and 18.1% of them had olfactory and taste disorders 5 days before the other clinical symptoms. No significant correlation was found between pulmonary symptoms and anosmia or ageusia. Olfactory and taste disorders are well known to be associated with a wide range of viral infections. The structural and genetic similarities between SARS-CoV-2 and other Coronaviruses suggest that they share common pathophysiologic mechanisms (Prompetchara et al., 2020). SARS-CoV-2 binds to olfactory epithelium, which is containing ACE2 receptors then invades the olfactory bulb (Benvenuto D. et al., 2020).

Gutiérrez-Ortiz et al reported two cases of Miller Fischer Syndrome and Polyneuritis Cranialis in Madrid (Gutiérrez-Ortiz et al., 2020). Direct invasion was not a possible explanation because of the negative CSF test for SARS-Cov-2. Otherwise, the immunological reaction could be, especially after detecting antibodies to gangliosides (GM1, GM2, GM3, GD1a, GD1b, GD3, GT1a, GT1b, GQ1b, and anti-sulfatide antibodies) in the serum of the Miller Fischer

case. The disease started few days after the infection. Improvement of cases by IVIG is a third clue to immunological explanation theory. Dinkin et al., 2020 reported two cases of ophthalmoparesis, one of them is Miller Fischer

Implications of COVID-19 on patients with Neurological diseases

The COVID-19 pandemic has forced a rapid and unprecedented reorganization of health service delivery for emergency worldwide (Waldman et al., 2020). One of these emergencies is CVS (Cerebrovascular stroke) which needs both rapid assessment and treatment. Baracchini et al reported 50% reduction in the TIAs (transient ischemic attacks) and minor strokes cases, compared to the same period in the last year. Also, they reported longer onset-to-door and door-to-treatment times for major strokes due to fear of people to get infection from hospitals. As a result, the number of patients who have undergone intravenous thrombolysis or bridging therapy (combined intravenous and thrombectomy) was decreased (26% and 30% respectively), while the number of primary thrombectomies was increased by 41%. Most of patients who had very serious strokes were arriving late, sometimes too late (Baracchini et al. 2020).

Another important point to note is that the Chinese Center of Disease Control and

Prevention reported that 1716 (3.8%) of 44,672 laboratory confirmed SARS-CoV-2 infections were healthcare providers (**Gutiérrez-Ortiz et al., 2020**). Additionally, in Italy, on 15 March 2020, there had been 2026 documented COVID-19 cases among healthcare providers (**Livingston et al., 2020**). Telemedicine and reorganization of work inside the hospitals were good decisions to reduce exposure of health provider to patients and maintaining the health services for other emergencies in a proper rapid manner. Many international panels and reports from different societies illustrated how to deal with stroke patients from entrance to discharging and how to perform what is called protected stroke code (**Fraser et al., 2020, Khosravani et al., 2020, Qureshi et al., 2020**). COVID-19 may exaggerate the symptoms of some neuromuscular disorders as Myasthenia gravis and autoimmune disease like Multiple sclerosis (MS). The big concern also is the immunosuppressive treatment in some neurological diseases. Fatal encephalitis occurred in immune-compromised patients with HCoV-OV43 (Human Corona Virus subtype OV43). In this patient, infection of neurons with HCoV-OV43 has been demonstrated at autopsy (**Morfopoulou et al., 2016**). Many inquiries were elicited regarding the safety of immune-modulating therapies in patients with MS, myasthenia gravis,

neuromyelitis optica, sarcoidosis and other disorders.

The American Academy of Neuromuscular and Electrodiagnostic Medicine (AANEM) published guidance regarding clinical visits, electrodiagnostic testing (EDX) and telemedicine during COVID-19 (**Guidon et al., 2020**). In conjunction with the National Medical Advisory Committee (NMAC), the National Multiple Sclerosis Society (NMSS) recently published recommendations regarding the use, continuation, and initiation of disease-modifying therapies (DMT). The Association of British Neurologists (ABN) has also published general advice related to DMT use in MS patients and immunosuppressive drugs (**Pérez et al., 2020**). The International Parkinson and Movement Disorder Society (IPMDS) reported its viewpoint regarding the care and treatment of Parkinson's disease (PD) (**Papa et al., 2020**). It encouraged the telemedicine for the follow up and visits of patients. It was preferred to postpone elective interventions like Deep Brain Stimulation (DBS). If direct patient contact visits are deemed necessary and urgent, precautions should be taken, including the use of personal protective equipment (PPE). Botulinum toxin injection is elective but may be necessary in patients with pain or disability (**Papa et al., 2020**). Psychological stress in this period may have a negative effect as regard the parkinsonian motor features and may decrease

the effect of dopaminergic drugs (Machtet et al., 2007, Stoessl et al., 2020). Reduction in physical exercise due to lockdown may aggravate the disease. At the end, future studies demonstrating the chronic state of the cured COVID-19 patients are predicted to depict a remote link with the neurological diseases such as MS or even PD, as they may be similar to encephalitis lethargica, which continued to be linked to the 1918 H1N1 pandemic (Henry et al., 2010).

Conclusion

COVID-19 is pandemic all over the world. It may be presented by neurological symptoms early even before the respiratory symptoms. It is crucial for neurologists to keep in mind these symptoms for achieving cautious dealing with the patients. The COVID-19 has its implications on other neurological diseases and their treatment. Further studies are warranted to discover more and more about the new virus SARS-CoV-2 and its remote implications.

References

- AK A. K; Gopaldas JA. (2020).** COVID-19 pandemic Let's gear up for the heavy battle Pulmon,22(1): 6-6.
- Avula A, Nalleballe K, Narula N, Sapozhnikov S, Dandu V, Toom S et al., (2020).** COVID-19 presenting as stroke. Brain, Behavior, and Immunity,87 (2020): 115-119.
- Baig AM, Khaleeq A, Ali U, Syeda H. (2020).** Evidence of the COVID-19 virus targeting the CNS: tissue distribution, host-virus interaction, and proposed neurotropic

mechanisms. ACS chemical neuroscience,11(7): 995-998.

Baracchini C, Pieroni A, Viaro F, Cianci V, Cattelan AM, Tiberio I et al., (2020). Acute stroke management pathway during Coronavirus-19 pandemic. Neurological Sciences,41(5):1003-1005.

Benvenuto D, Giovanetti M, Ciccozzi A, Spoto S, Angeletti S, Ciccozzi M.(2020). The 2019-new coronavirus epidemic: evidence for virus evolution. Journal of medical virology, 92(4):455-9.

Beyrouti, R, Adams ME, Benjamin L, Cohen H, Farmer SF, Goh YYF et al.,(2020). Characteristics of ischaemic stroke associated with COVID-19. Journal of Neurology, Neurosurgery & Psychiatry,91(8): 889-891.

Brun G, Hak JF, Coze S, Kaphan E, Carvelli J, Girard N et al., (2020). COVID-19—White matter and globus pallidum lesions: Demyelination or small-vessel vasculitis? Neurology-Neuroimmunology Neuroinflammation,7(4).

Chan J, Kok K, Zhu Z,Chu H. (2020). Genomic characterization of the 2019 novel human pathogenic coronavirus isolated from a patient with atypical pneumonia after visiting Wuhan. Emerg Microbes Infect,9(1): 221-236.

Chan M, Han SC, Kelly S, Tamimi M, Giglio B, Lewis A. (2020). A case series of Guillain-Barré Syndrome following Covid-19 infection in New York. Neurology: Clinical Practice.

Cao Y, Li L, Feng Z, Wan S, Huang P, Sun X. (2020). Comparative genetic analysis of the novel coronavirus (2019-nCoV/SARS-CoV-2) receptor ACE2 in different populations. Cell Discovery, 6(1):1-4.

Dinkin, M, Gao V, Kahan J, Bobker S, Simonetto M, Wechsler P et al., (2020).

COVID-19 presenting with ophthalmoparesis from cranial nerve palsy. *Neurology*,95(5): 221-223.

Ebrahimzadeh SA, Ghoreishi A, Rahimian N.(2020). Guillain-Barré Syndrome associated with the coronavirus disease 2019 (COVID-19). *Neurology: Clinical Practice*.

Fraser JF, Arthur AS, Chen M, Levitt M, Mocco J, Albuquerque FC et al.,(2020).Society of NeuroInterventional Surgery recommendations for the care of emergent neurointerventional patients in the setting of covid-19. *Journal of neurointerventional surgery*, 12(6): 539-541.

Giacomelli A, Pezzati L, Conti F, Bernacchia D, Siano M, Oreni L et al., (2020). Self-reported olfactory and taste disorders in patients with severe acute respiratory coronavirus 2 infection: a cross-sectional study. *Clinical Infectious Diseases*, 71(15), 889-890

Guan W, Ni Z, Hu Y, Liang W, Ou C, He J, Liu L et al., (2019).Clinical characteristics of coronavirus disease 2019 in China. *New England journal of medicine* 382(18): 1708-1720.

Guidon AC; Amato AA.(2020). COVID-19 and neuromuscular disorders. *Neurology*, 94(22): 959-969.

Guo YR, Cao QD, Hong ZS, Tan YY, Chen SD, Jin HJ al., (2020). The origin, transmission and clinical therapies on coronavirus disease 2019 (COVID-19) outbreak—an update on the status. *Military Medical Research*,7(1): 1-10.

Gutiérrez-Ortiz, C, Méndez A, Rodrigo-Rey S, San Pedro-Murillo E, Bermejo-Guerrero L, Gordo-Mañas R et al.,(2020).Miller Fisher Syndrome and polyneuritis cranialis in COVID-19. *Neurology*,95(5): 601-605.

Helms J, Kremer S, Merdji H, Clere-Jehl R, Schenck M, Kummerlen C, et al., (2020) Neurologic features in severe SARS-CoV-2 infection. *New England Journal of Medicine*, 382(23), 2268-2270.

Dhesi S, Shanks M, Tymchak WJ. (2015). Troponin rise in hospitalized patients with non-acute coronary syndrome: retrospective assessment of outcomes and predictors. *Can J. Cardiol*, 31:296–301.

Henry J, Smeyne RJ, Jang H, Miller B; Okun MS. (2010). Parkinsonism and neurological manifestations of influenza throughout the 20th and 21st centuries. *Parkinsonism & related disorders* 16(9): 566-571.

M Kalia; Mesulam MM. (1980). Brain stem projections of sensory and motor components of the vagus complex in the cat: II. Laryngeal, tracheobronchial, pulmonary, cardiac and gastrointestinal branches. *Journal of Comparative Neurology*,193(2): 467-508.

Karimi N, Sharifi Razavi A,Rouhani N. (2020). Frequent convulsive seizures in an adult patient with COVID-19: a case report. *Iranian Red Crescent Medical Journal*(In Press).

Kaye R, Chang CD, Kazahaya K, Brereton J,Denneny JC III. (2020). COVID-19 anosmia reporting tool: initial findings. *Otolaryngology–Head and Neck Surgery*, 163(1): 132-134.

Khosravani H, Rajendram P, Notario L, Chapman M G,Menon BK. (2020). Protected code stroke: hyperacute stroke management during the coronavirus disease 2019 (COVID-19) pandemic. *Stroke*, 51(6), 1891-1895.

LechienJR, Chiesa-Estomba CM, De Siaty DR, Horoi M, Le Bon SD, Rodriguez et al., (2020). Olfactory and gustatory dysfunctions as a clinical presentation of mild-to-moderate

forms of the coronavirus disease (COVID-19): a multicenter European study. *European Archives of Oto-Rhino-Laryngology*, 277(8): 2251-2261.

Letko MA, Marzi, Munster V. (2020). Functional assessment of cell entry and receptor usage for SARS-CoV-2 and other lineage B betacoronaviruses. *Nature microbiology*,5(4): 562-569.

LiYC, Bai WZ, Hirano N, Hayashida TT, Hashikawa (2012). Coronavirus infection of rat dorsal root ganglia: ultrastructural characterization of viral replication, transfer, and the early response of satellite cells. *Virus research*, 163(2): 628-635.

Libbey JE, Kennett NJ, Wilcox KS, White HS, Fujinami RS. (2011). Interleukin-6, produced by resident cells of the central nervous system and infiltrating cells, contributes to the development of seizures following viral infection. *Journal of virology*,85(14): 6913-6922.

Livingston E; Bucher K. (2020). Coronavirus disease 2019 (COVID-19) in Italy. *Jama*,323(14): 1335-1335.

Macht M, Kaussner Y, Möller JC, Stiasny-Kolster K, Eggert KM, Krüger HP et al.,(2007). Predictors of freezing in Parkinson's disease: a survey of 6,620 patients. *Movement Disorders*,22(7): 953-956.

Mao L, Wang M, Chen S, He Q, Chang J, Hong CY et al., (2020). Neurological manifestations of hospitalized patients with COVID-19 in Wuhan, China: a retrospective case series study.

Mehta P, McAuley DF, Brown M, Sanchez E, Tattersall RS, Manson JJ. (2020). COVID-19: consider cytokine storm syndromes and immunosuppression. *The Lancet*,395(10229): 1033-1034.

Morelli N, Rota E, Terracciano C, Immovilli P, Spallazzi M, Colombi D et al.,(2020). The baffling case of ischemic stroke disappearance from the casualty department in the COVID-19 era. *European neurology*, 1.

Morfopoulou S, Brown JR, Davies EG, Anderson G, Virasami A, Qasim W. et al., (2016). Human coronavirus OC43 associated with fatal encephalitis. *New England Journal of Medicine*,375(5): 497-498.

Moriguchi TN, Harii J, Goto D, Harada H, Sugawara J, Takamino et al., (2020). A first case of meningitis/encephalitis associated with SARS-Coronavirus-2. *International Journal of Infectious Diseases*,94: 55-58.

Oxley TJ, Mocco J, Majidi S, Kellner CP, Shoirah H, Singh IP et al.,(2020). Large-vessel stroke as a presenting feature of Covid-19 in the young. *New England Journal of Medicine*,382:(20), e60.

Papa SM, Brundin P, Fung VS, Kang UJ, Burn DJ, Colosimo C et al., (2020). Impact of the COVID-19 pandemic on Parkinson's disease and movement disorders. *Mov Disord* 6:(10.1002).

Pérez C A. (2020). Looking ahead: The risk of neurologic complications due to COVID-19. *Neurology, Clinical Practice*.

Poyiadji N, Shahin G, Noujaim D, Stone M, Patel S, Griffith B, (2020). COVID-19–associated acute hemorrhagic necrotizing encephalopathy: CT and MRI features. *Radiology*,296(2):E119-E120

Promptchara E, Ketloy C, Palaga T. (2020). Immune responses in COVID-19 and potential vaccines: Lessons learned from SARS and MERS epidemic. *Asian Pac J Allergy Immunol*,38(1): 1-9.

Qureshi AI, Abd-Allah F, Alsenani F, Aytac E, Borhani-Haghighi A, Ciccone, et al.,

(2020). Management of acute ischemic stroke in patients with COVID-19 infection: Report of an international panel. *International Journal of Stroke*, 15(5): 540-554.

Stoessl AJ, Bhatia KP, Merello M. (2020). Movement Disorders in the World of COVID-19. *Movement Disorders Clinical Practice*.

Tang C, Zhang K, Wang W, Pei Z, Liu Z, Yuan P et al.,(2020). Clinical Characteristics of 20,662 Patients with COVID-19 in mainland China: A Systemic Review and Meta-analysis, medRxiv.

Torbic H; Duggal A. (2019).Neuromuscular blocking agents for acute respiratory distress syndrome. *Journal of critical care*,49: 179-184.

Toscano G, Palmerini F, Ravaglia SL, Ruiz P, Invernizzi M, Cuzzoni Get al., (2020). Guillain–Barré syndrome associated with SARS-CoV-2. *New England Journal of Medicine*,382(26): 2574-2576.

Turtle L. (2020). Respiratory failure alone does not suggest central nervous system invasion by SARS-CoV-2. *Journal of Medical Virology*,92(7): 705-706.

Vaira LA, Deiana G, Fois AG, Pirina P, Madeddu G, De Vito A et al., (2020). Objective evaluation of anosmia and ageusia in COVID-19 patients: Single-center experience on 72 cases. *Head & neck*, 42(6): 1252-1258.

Waldman G, Mayeux R, Claassen J, Agarwal S, J. Willey, E. Anderson, P. et al., (2020). Preparing a neurology department for SARS-CoV-2 (COVID-19): Early experiences at Columbia University Irving Medical Center and the New York Presbyterian Hospital in New York City. *Neurology*,94(20): 886-891.

Warren-Gash C, Blackburn R, Whitaker H, McMEnamin J, Hayward AC.(2018).Laboratory-confirmed respiratory infections as triggers for acute myocardial

infarction and stroke: a self-controlled case series analysis of national linked datasets from Scotland. *European Respiratory Journal*,51(3):1701794.

Wong A, Simon E, Zimmerman R, Wang HS, Toh CH, Ng SH. (2006). Acute necrotizing encephalopathy of childhood: correlation of MR findings and clinical outcome. *American journal of neuroradiology* 27(9): 1919-1923.

Xiang P, Xu X, Gao L, Wang H, Xiong H, Li R. (2020). First case of 2019 novel coronavirus disease with encephalitis. *ChinaXiv 202003: 00015.*

Xu Z, Shi L, Wang Y, Zhang J, Huang L, Zhang Cet al., (2020). Pathological findings of COVID-19 associated with acute respiratory distress syndrome. *The Lancet respiratory medicine*,8(4): 420-422.

Yan CH, Faraji F, Prajapati DP, Boone CE, DeConde AS. (2020). Association of chemosensory dysfunction and Covid-19 in patients presenting with influenza-like symptoms. *International forum of allergy & rhinology*,Vol. 10.No. 7. 2020.

YeM, Ren Y, Lv T. (2020). Encephalitis as a clinical manifestation of COVID-19. *Brain*, behavior, and immunity.

Yin R, Feng W, Wang T, Chen G, Wu T, Chen D, Lv T, Xiang D, (2020). Concomitant neurological symptoms observed in a patient diagnosed with coronavirus disease 2019. *Journal of medical virology*,92(10): 1782-1784.

Zhao K, Huang J, Dai D, Feng Y, Liu L, Nie S. (2020). Acute myelitis after SARS-CoV-2 infection: a case report. *MedRxiv*.