

## Effect of Aging on the Histological Structure of the Duodenum Wall in Male Albino Rats

**Rania A. M. Ali<sup>a</sup>, Eman A. Abdelrahim<sup>a</sup>, Yasser A. G. Ahmed<sup>b</sup>, Soha M. Abdel-lateif<sup>b</sup>**

<sup>a</sup>Department of Histology, Faculty of Medicine, South Valley University, Qena, Egypt.

<sup>b</sup>Department of Histology, Faculty of Veterinary Medicine, South Valley University, Qena, Egypt.

### **Abstract:**

**Background:** Aging is a phenomenon that presents various alterations in neurochemical, behavioral and physiological processes.

**Objectives:** This study aimed to evaluate the effect of aging on the histology of the duodenum of male albino rats.

**Materials and methods:** thirty male albino rats will be divided into three groups according their age. Group A: Ten male albino rats (adult aged) at the age of 4 months. Group B: Ten albino rats (middle aged) at the age of 8 months. Group C: Ten albino rats (old aged) at the age of 18 months. At the end of the experimental period, the animals were anaesthetized, then the duodenum was dissected out and specimens were processed for histological examination.

**Results:** At the age of 4 months shrinkage in the core of the villus was recorded in the duodenum of rats. While deterioration in submucosal layer and deterioration in muscularis layer were seen in rats aged 8 months, in addition to congestion in mucosa. Many histological changes were observed in rats aged 18 months beginning from congestion in submucosa and deterioration of muscle fibers in muscularis reaching congestion in mucosa and inflammation in crypts region and ending with necrosis in crypts and villi.

**Conclusion:** From the present study it is concluded that, as age advances in male rats, a significant histological change involved the duodenum and at age 18 months the histological changes were more and obvious.

**Key words:** Aging; duodenal wall; males; Rats

### **Introduction:**

Aging is simply a process which is characterized by the degeneration of essential functions in late or post reproductive phase of all multicellular organisms (Schafer et al., 2006; Sohal, 2002). It is characterized by a progressive decline in function and a decrease in the body's ability to maintain homeostasis (Gad et al., 2013; Salmon et al., 2010).

The small intestine is a specialized tubular structure within the abdominal cavity in continuity with the stomach proximally and the colon distally. The duodenum, the most proximal portion of the small intestine, begins

at the duodenal bulb, travels in the retroperitoneal space around the head of the pancreas and ends on its return to the peritoneal cavity at the ligament of Treitz. The remainder of the small intestine is suspended within the peritoneal cavity by a thin, broad based mesentery that is attached to the posterior abdominal wall and allows free movement of the small intestine within the abdominal cavity (Kierszenbaum et al., 2016). According to the "aging free radical theory," introduced by Harman (1956), aging is caused by an accumulative enhancement of the oxidative stress at various organs (Gomez

et al., 2004), tissues and cell components (Rosa et al.,2005).

#### **Material and methods:**

##### **1. Animals:**

Thirty male albino rats will be divided into three groups according their age. Group A: Ten male albino rats (adult aged) at the age of 4 months. Group B: Ten albino rats (middle aged) at the age of 8 months. Group C: Ten albino rats (old aged) at the age of 18 months.

The animals are maintained in the animal house under normal day and night cycles and appropriate temperature, fed rat chow ad libitum, and allowed free access of water.

##### **2. Tissue processing and staining:**

Animals will be sacrificed at the appropriate age in the histology department at faculty of medicine in qena. The animals will be anesthetized with ether; their hearts will be exposed and perfused with saline until the flowing blood is cleared. The perfusion will be completed with 10% formalin.

The duodenum will be immediately taken from each animal. Small pieces of the duodenum will be fixed in 10% formalin and Bouin's solution, dehydrated in graded alcohols, cleared in methyl benzoate and embedded in paraplast. Tissue blocks will be sectioned into 5 µm thick slices using a Leica microtome and stained with the following staining methods:

- Haematoxylin and eosin for routine histological examination.
- PAS (Periodic acid Schiff) for staining of goblet cells and neutral mucopolysaccharides.

All steps of tissue preparation and staining methods will be done according to Drury and Wallington (1980).

##### **3. Morphometric study:**

Morphometric study was carried out by measuring the length of the villi in

adult, middle and old age. Measurements were recorded from at least five H&E-stained slides. Finally, the average value for the length of the villus was calculated for each slide.

##### **4. Statistical analysis:**

Data were statistically analyzed using Microsoft Excel 2013 through the descriptive statistics (summary statistics) and analysis of variance single factor test. *P*-values less than 0.05 were considered statistically significant and *P*-values less than 0.001 were considered highly statistically significant.

#### **Results:**

##### **Hematoxylin and Eosin:**

At the age of 4 months shrinkage in the core of the villus was recorded in the duodenum of rats (Figure1). While and deterioration in submucosal layer and deterioration in muscularis layer was seen in rats aged 8 months, in addition to congestion in mucosa. (Figure2). Many histological changes were observed in rats aged 18 months beginning from congestion in submucosa and deterioration of muscle fibers in muscularis reaching congestion in mucosa and inflammation in crypts region and ending with necrosis in crypts and villi with inflammatory cells. (Figure3).

##### **PAS (Periodic acid Schiff):**

At the age of 4 months, it shows well delineated PAS positivity of the brush border of the villi, PAS positive goblet cells of both villi and crypts (Figure.4). And in rats aged 8 months, it shows intense PAS positive goblet cells of both villi and crypts, and intense thick positivity of the luminal border of acini of Bruner's glands (Figure.5). At the age of 18 months, that number of goblet cells and its content in the villi of group III are less than group II and positivity of the luminal border

of acini of Bruner's glands group III are less than group II (Figure.6).

### Morphometric analysis:

It revealed that the length of the villi increased by age. In group I, the length of the villi ranged from 222.8 to 257.7 $\mu$ m and by the mean  $\pm$  SD of (243.38 $\pm$ 10.6). In group II, the length of the villi ranged from 222.8 to 293.8  $\mu$ m and by the mean  $\pm$  SD of (259.99 $\pm$ 18.9) . In group III, the length of the villi ranged from 232.63 to 313.6 by the mean  $\pm$  SD of (273. 9 $\pm$ 24.1).(Table.1)

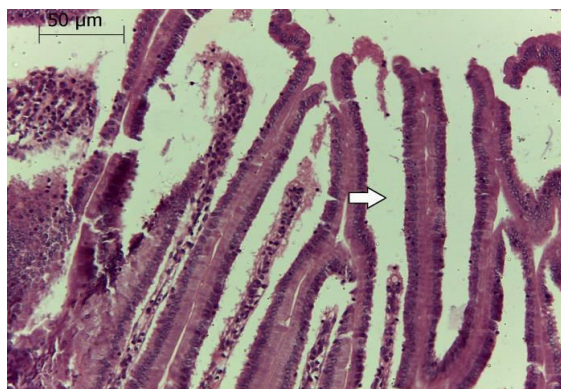
**Table (1): The length of the villi in the studied groups.**

	Length of villi		
	Group I	Group II	Group III
<b>Mean <math>\pm</math>SD</b>	243.38 $\pm$ 10.6	259 $\pm$ 18.9	273 $\pm$ 24.1
<b>Range</b>	222.8-257.7	222.8-293.8	232.63-313.6

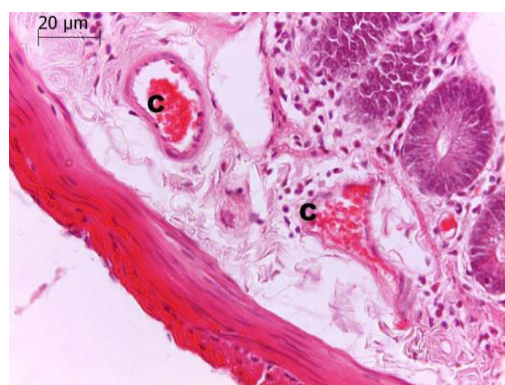
Group I vsGoup II P-Value is 0.000334929

Group I vsGoup III P-Value is 0.00002637

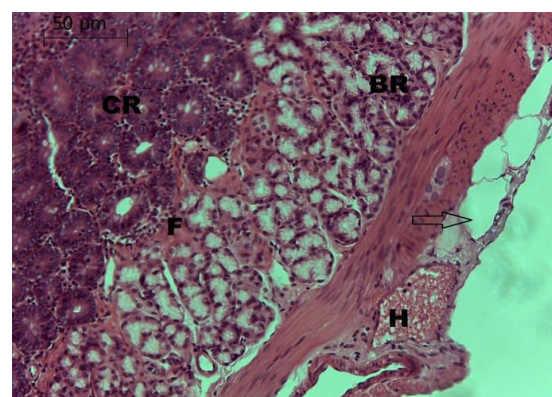
Group II vsGoup III P-Value is 0.00002428



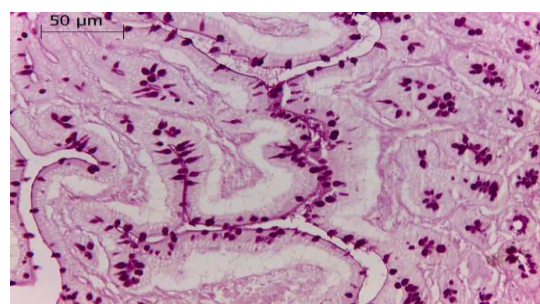
**Figure 1:** A photomicrograph of Transverse section of duodenum of rat aged 4 months showing; (arrow) shrinkage of the core of the villi. (H&E stain, X 200)



**Figure 2:** Transverse section of duodenum of rat aged 8 months showing; C: congestion in blood vessels in of submucosal layer). (H&E stain, X 400)

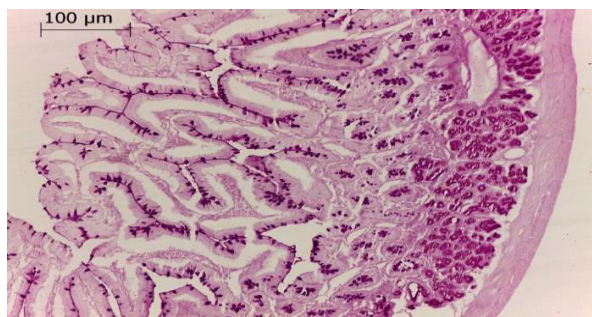


**Figure 3:** Atransverse section of duodenum of rat aged 18 months showing; disintegration in muscularis layer (arrow) ; (H) haemorrhage between muscle fibers and (F) fibrosis between brunner's glands (BR) . (H&E stain, X 200)

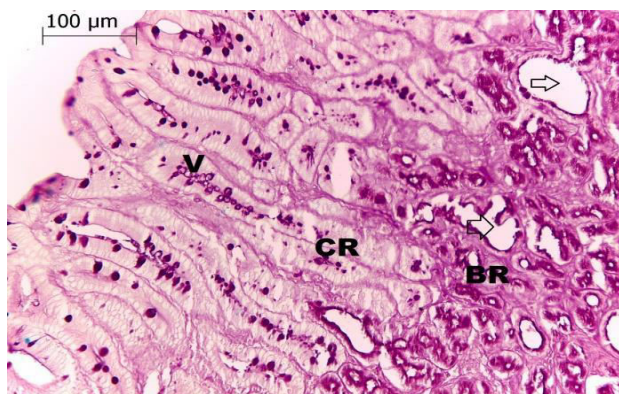


**Figure 4:** A transverse section of the duodenum of rat aged 4 months (Group I) showing; well delineated PAS positivity of the brush border of the villi, PAS positive goblet cells of both villi and crypts. (PAS, X200)





**Figure 5:** A transverse section of the duodenum of rat aged 8 months (Group II) showing; intense PAS positive goblet cells of both villi and crypts, and intense thick positivity of the luminal border of acini of Bruner's glands. (PAS, X100)



**Figure 6:** A transverse section of the duodenum of rat aged 18 months (group III) showing; that number of goblet cells and its content in the villi of group III are less than group II. Note cystic changes appear between crypts and brunner's glands (arrow). (PAS, X100)

#### Discussion:

The incidence of duodenal ulcer increases with age (Kim et al., 1990). Some studies suggest that impaired duodenal mucosal secretion of bicarbonate is an important factor in the pathogenesis of duodenal ulcer (Thomas et al., 1989). It is observed that aging has a significant effect on histological structures of duodenum. Aging is a process that presents various alterations in behavioral, physiological and neurochemical processes (Bolling et al., 2011; Hedden et al., 2004).

In this study, we observed increase in mucosal mass of duodenum rats aged 18 months than 8 months and 4 months. Raul et al., (1988) found that the intestinal segments of the senescent rats contained higher mucosal mass and protein content compared with the young and mature animals.

In this study, it was found gradually increase in the length of villi of the duodenum by aging that found in studies of Vigueraset al., (1999) that indicate in their study, which was performed in 69 male Wistar rats with ages ranging from one day to one year old, that the length of villi in the small intestine gradually increased.

In this study, it was observed well delineated brush border of the villi in the duodenum of rat aged 8 months then became less delineated brush border in the duodenum of rat aged 18 months, that agree with studies of Jang et al., (2000) that found in an electron microscopic examination, that morphologically a less dense brush border membrane (BBM) structure in the duodenum of rats aged 23 months was detected than that of rats aged 5 months.

#### Conclusion:

From the present study it is concluded that, as age advances in male rats, significant histological changes involved the duodenum and at age 18 months the histological changes were more and obvious.

#### References:

- Al-Qudah MM. (2014). Histological Effects of Aging on Male Albino Rats Duodenum, World Journal of Medical Sciences, IDOSI Publications pages: 174-178.
- Bolling BW, Court HM, Blumberg JB, Chen CYO. (2011). Microsomal Quercetin Glucuronidation in Rat Small Intestine Depends on Age and Segment. Drug

Metabolism and Disposition, 39 (8): 1406-1414.

**Drury RAB, Wallington EA. (1980).** Carelton's Histology technique, 5th Edition. Oxford University Press, Oxford. New York. Toronto, 283-289.

**Ehrenrink G, Schafer F, Boeira T, Pilla A, Rodrigues M, SilveiraM. (2006).** Antioxidant enzymes activities and protein damage in rat brain of both sexes. Experimental Gerontology, 41: 368-371.

**Gad SB, Zaghloul DM. (2013).** Beneficial Effects of Green Tea Extract on Liver and Kidney Functions, Ultrastructure, Lipid Profile and Hematological Parameters in Aged Male Rats. Global Veterinaria, 11(2): 191-205.

**Harman D. (1956).** Aging: a theory based on free radical and radiation chemistry. J. Gerontol., 2: 298-300.

**Hedden T, Gabrieli JD. (2004).** Insights into the ageing mind: a view from cognitive neuroscience, Nat. Rev. Neurosci., 5: 87-96.

**Jang I, Jung K, ChoJ. (2000).** Influence of age on duodenal brush border membrane and specific activities of brush border membrane enzymes in Wistar rats. Experimental Animals, 49(4): 281-287.

**KierszenbaumAL, TresLL. (2016).** Histology and Cell Biology An Introduction to Pathology, Elsevier, Fourth Edition, p 499-519.

**Kim SW, Parekh D, Townsend CM, Thompson JC. (1990).** Effects of Aging on Duodenal Bicarbonate Secretion. Ann. Surg., 212(3): 332-337.

**Navarro A, Gomez C, Lopez-Cepero JM, BoverisA. (2004).** Beneficial effects of moderate exercise on mice aging: survival, behavior, oxidative stress, and mitochondrial electron transfer. Am J. Physiol.

Regul.Integr.Comp. Physiol., 286: R505-R511.

**Raul F, Gosse F, Doffoel M, DarmentonP. (1988).** Age related increase of brush border enzyme activities along the small intestine. Gut., 29: 1557-1563.

**Rosa EF, Silva AC, Ihara SSM, Mora OA, Aboulafia J, Nouailhetas VLA.(2005).** Habitual exercise program protects murine intestinal, skeletal, and cardiac muscles against aging. J. Appl. Physiol., 99: 1569-1575.

**Salmon AB, Richardson A, Pérez VI.(2010).** Update on the oxidative stress theory of aging: does oxidative stress play a role in aging or healthy aging? Free Radical Biology and Medicine, 48: 642-655.

**Sohal RS.(2002).** Role of oxidative stress and protein oxidation in the aging process. Free Radical Biology values showed no statistical difference from control aged and Medicine, 33: 37-44.

**Vigueras RM, Rojas-Castaneda J, Hernandez R, Reyes G, AlvarezC. (1999).** Histological characteristics of the intestinal mucosa of the rat during the first year of life. Laboratory Animals, 33: 393-400.

**Wolosin JD, Thomas FJ, Hogan DL, Koss MA, Dorisio TMO, Isenberg JI. (1989).** The effect of vasoactive intestinal peptide, secretin and glucagon vasoactive intestinal peptide, secretin and glucagon on human duodenal bicarbonate secretion.Scand J.Gastroenterol., 24: 151-153.