

Placental Pathology in Pregnancy-Induced hypertension

Amany M. Mohamed^a, Abd El-Naser.A. Ali^b, Magda H. Nasreldin.^c

^aPathology Department, Faculty of Medicine, South Valley University, Qena, Egypt

^bObstetrics & Gynecology Department, Faculty of Medicine, South valley University Qena, Egypt

^cPathology Department, Faculty of Medicine, Ain Shams University, Cairo, Egypt

Abstract:

Background: Hypertensive disorder in pregnancy is reflected in placenta in a significant way both macroscopically and microscopically.

Study Design: A prospective observational study.

Study setting: Pathology department in collaboration with the Obstetrics and Gynecology department at Qena university hospital, South Valley University, Qena, Egypt.

Duration: From May 2019 to August 2020.

Patients and method(s): This study was conducted on 50 cases of pregnant women with hypertension (mild, severe, eclampsia) and placental changes detected microscopically by H&E stain.

Result(s): among 50 placentas studied, we found that infarction present in 16(59.3%) cases of mild hypertension, 10(62.5%) cases of severe hypertension and 7 (100.0%) cases of eclampsia. Calcification was found in 9(33.3%) cases of mild hypertension, 12(75.0%) cases of severe hypertension and 7(100.0%) cases of eclampsia.

Conclusion: calcification and infarction were present in placenta of hypertensive pregnant women and increased with increased severity of hypertension.

Keywords: Pregnancy Induced Hypertension, Placental Pathology.

Introduction:

Placenta is a new organ formed during pregnancy in the uterus that serves as an intermediary between the fetus and the mother. It is considered as a vital organ for maintaining and continuing the healthy pregnancy that it aids the gaseous exchange between mother and fetus and also facilitates the provision of the nutrients to fetus. (Salih and Omar, 2017).

It can play as a key role in enhancing the normal growth and the normal development of the fetus. Therefore, anything that can affect its development and function may cause a deleterious effect on the fetus and its ability to cope with its

intrauterine environment. (Gudeet al., 2004).

Also the placenta is a vital source for hormone production such as progesterone

and human chorionic gonadotropin which maintain the pregnancy. Soplacental dysfunction can lead to many adverse fetal outcomes (Blackbur, 2013).

Hypertensive disorder in pregnancy is reflected in placenta in a prominent significant way both macroscopically and microscopically. Several studies had shown that placental blood flow was decreased in pregnancy induced hypertension due to maternal vascular vasoconstriction. (Ahmed and Daver, 2013).

This study aimed to investigate the extent of placental changes associated with various hypertensive disorders in pregnancy.

Patients and methods:

This was a prospective study performed at Pathology department in collaboration with Obstetrics and Gynecology department in Qena university hospital, South Valley University, Qena, Egypt. The study was conducted on 50 pregnant women with different degree of hypertensive disorders ranged from mild gestational hypertension to severe preeclampsia and eclampsia, the patients that included in this study were conducted from those attendant obstetrics ward in obstetrics and gynecology department. The study was performed from May 2019 to August 2020 (14 months).

Inclusions criteria:

1. Age between 18 and 45 years old
2. Gestational age ≥ 28
3. Diagnosed to have hypertensive disorder with pregnancy including gestational hypertension, pre- eclampsia, eclampsia and chronic hypertension.

Exclusion criteria:

1. Multiple pregnancy
2. Women with other disorders; diabetes mellitus, hyperthyroidism, abruptio placenta, jaundice or intrauterine infection.

Methods:

Full history was taken from all patients included in this study with full examination (general, abdominal, obstetric and local examination) plus vital signs included pulse, BP, temp. and resp. rate. Blood pressure was measured in sitting or left later position in 2 occasions 6 hours apart with mental and physical rest. Full laboratory investigations were done included, CBC, renal and liver function tests, urine analysis and fundus examination. The placentas from both vaginal and cesarean deliveries will be included. Immediately after the delivery, once the placenta is delivered, it will be

washed in the running tap water. The placenta will be preserved in 10% buffered formalin saline and then will be transported to Pathology Department

At pathology laboratory, serial sections of suspicious sites of placenta, and random sections were taken. Tissue sections were examined histopathologically by routine H&E stain. Gross and microscopic examination of the placenta was done.

Statistical analysis:

Recorded data were analyzed using the statistical package for social sciences, version 20.0 (SPSS Inc., Chicago, Illinois, USA). Quantitative data were expressed as mean ± standard deviation (SD). Qualitative data were expressed as frequency and percentage.

Results:

Table 1: clinical data of the studied group

Type of hypertension No (%)	27 (54.0%)
• Mild PET	16 (32.0%)
• Severe PET	7 (14.0%)
• eclampsia	
Age in years Mean+ STD	28.98±5.83
Parity Mean+ STD	1.6±1.2
Date of delivery No (%)	21 (42.0%)
• before 37w	29 (58.0%)
• after 37w	
Fetal outcome	
• Normal	27 (54.0%)
• IUGR	10 (20.0%)
• LBW	11 (22.0%)
• IUFD	2 (4.0%)

This table shows prevalence rate of hypertension, 54% of hypertensive pregnant

women (N=27) have mild PET, but 32% (N=16) of them have severe PET and 14% (N=7) have eclampsia.

The age of participating ranged with a mean of 28.98 ± 5.38 years.

The distribution of date at delivery between the participating patients was 42% (N=21) delivered after 37 weeks and 58% (N=29) delivered after 37 weeks.

Table 2: pathological changes occurred in the studied group

Variable	No (%)
Calcification	22 (44.0%)
Infarction	17 (34.0%)
Thrombosis	14 (28.0%)
Retro placental hemorrhage	19 (38.0%)
Syncytial knots	26 (52.0%)
Fibrinoid necrosis	25 (50.0%)

This table showed that the percentage of placentae with calcification was 44% (N=22), the percentage of placentae with infarction was 34% (N=17), the percentage of placentae with thrombosis was 28% (N=14), the percentage of placentae with retroplacental hemorrhage was 38% (N=19), the percentage of placentae with syncytial knots was 52% (N=26) and the percentage of placenta with fibrinoid necrosis was 50% (N=25).

Table 3: Pathological changes Comparison among the studied groups of different types of hypertension

Variable	Mild PET	Severe PET	Eclampsia	P value
Calcification	9(33.3%)	12(75.0%)	7(100.0%)	.000*
Infarction	16(59.3%)	10(62.5%)	7	.04

n	3%	5%	(100.0%)	0*
Thrombosis	16(59.3%)	14(87.5%)	6(85.7%)	.05*
Retroplacental hemorrhage	12(44.4%)	13(81.3%)	6(85.7%)	.02*
Syncytial knots	12(44.4%)	6(37.5%)	6(85.7%)	.089
Fibrinoid necrosis	10(37.0%)	12(75.0%)	3(42.9%)	.05*

****Chi-square test was used to compare proportions between groups**

***means (p < 0.05).**

There was statistically significant relationship between placental calcification and type of hypertension where calcification in mild PET was absent in 18(66.7%) and present in 9(33.3%) while calcification in severe PET was absent in 4(25%) and present in 12(75%) (P value =0.000).

There was statistically insignificant relationship between syncytial knots and type of hypertension where in mild PET it was absent in 15(44.6%), present in 12(44.4%). In severe PET it was absent in 10(62.5%) and present in 6(37.5%). In eclampsia it was absent in 1(14.3%) and present in 6(85.7%) (P value=0.089).

Table 4: correlation between type of hypertension and its effect on placental pathological changes and fetal outcome

Variable	r*	P value
Calcification	.519*	.000*
date at delivery	.469*	.001
fetal outcome	.438*	.001
RetroplacentalHe	.385*	.006
Thrombosis	.292*	.040
Fibrinoid necrosis	.214	.135
Syncytial	.157	.275

***Spearman's Rank Correlation Coefficient,
*means ($p < 0.05$).**

There is significant Positive moderate correlation between type of hypertension and calcification ($r=.519^{**}$, p value=.000) FigR-8 mean that when degree of hyper changes increased ,placental calcification increased , date at delivery ($r=.469^{***}$, p value=.001) and fetal outcome ($r=.438^{**}$ p value=.001).There is significant Positive weak correlation between type of hypertension and retroplacental hemorrhage ($r=.385^{**}$, p value=.006) ,thrombosis ($r=.292^*$, p value=.04).

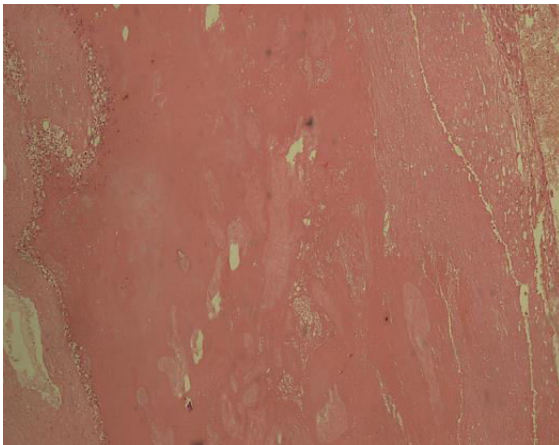


Figure (1):Photomicrograph showing placental infarction (H&E x200).

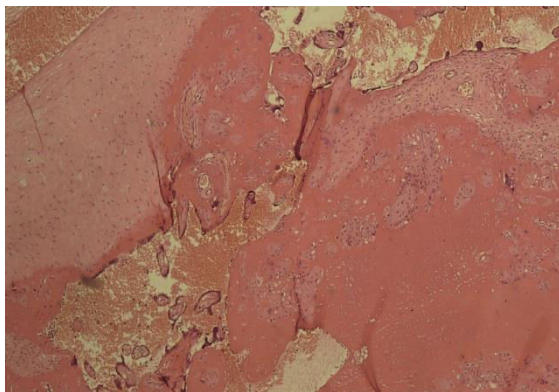
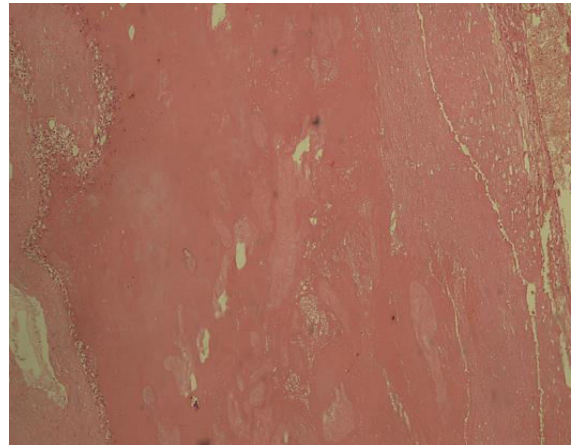
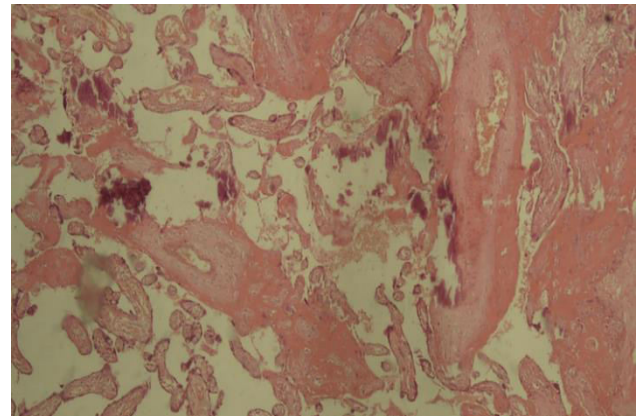


Figure (2): Photomicrograph showing fibrinoid necrosis (H&E x200).



Figure(3): Photomicrograph showing placental infarction (H&E x200).



Figure(4): Photomicrograph showing Placental calcification (H&E x200).

Discussion:

Histological abnormalities such as the presence of calcification, placental infarction, thrombosis, and What were observed significantly more often in the hypertensive placentas, The aim of this study was to investigate the extent of placental changes (gross and microscopic changes) associated with various hypertensive disorders in pregnancy.

So that we assessed defined several histological abnormalities in placentas of mild and severe PET groups. The observations were correlated well with the previous studies done by various Authors.

In the current study, maximum of 27 (54%) cases belonged to mild PET, 16 (32%) cases belonged to severe PET, and minimum of 7 (14%) cases were of eclampsia.

In the present study, the mean ages were 28.98 (SD=5.83). this was in agreement with other studies as (MehareandKebede, 2020) which found that the mean ages of the mothers of PIH were 27.12 years.

In present study, placental infarctions present in 16 cases (59.3%) of mild PE, in 10 cases (62.5%) of severe PET and in 7 cases (100.0%) cases of eclampsia. These results are near to the results of (Krielessi et al., 2012) where the results were 40% in mild PET and 72.72% in severe PET. While (Kambale et al., 2016) found different results, placental infarction was seen in only 28.8% placentae from PIH group.

Also, the results of (Ezeigwe et al., 2018) comes against our results, it showed that placentas in eclampsia, severe preeclampsia, mild preeclampsia, there was respective increase in the presence of any infarction (75%, 66.7%, 35.7%).

Placental calcifications in our study present in 9 cases (33.3%) of mild PET and 12 cases (75.0%) of severe PET and 7 cases (100.0%) of eclampsia while the results of (Krielessi et al., 2012) were 32.72% for severe hypertension and 25.45% in mild hypertension that is against our results.

In our study villous fibrinoid necrosis present in 10 cases (37.0%) of mild PET, 12 cases (75.0%) of severe PET and 3 cases (42.9%) of eclampsia. These results are near to the results of (Krielessi et al., 2012) where 72.72% in severe hypertension, 32.72% in mild hypertension. While for (Kambale et al., 2016) 75% of cases of eclampsia and

53.3% cases of severe PIH showed fibrinoid necrosis; against our study.

According to (Krielessi et al., 2012) thickened vessels with "thrombosis" was present in 25.45% of severe hypertension and 23.63% of mild hypertension, this comes in contrary with Our study which showed that thrombosis present in 16 cases (59.3%) of mild PET, 14 cases (87.5%) of severe PET and 6 cases (85.7%) of eclampsia.

Our study concluded that syncytial knots present in 12 cases (44.4%) of mild PET, in 6 cases (37.5%) of severe PET and in 6 cases (85.7%) of eclampsia this comes in agreement with (Kambale et al., 2016) which showed that All the cases of severe PIH and eclampsia showed syncytial knots of >30%, while only (38.4 %) of mild PIH showed the same. In the PIH group, (35.5%) showed presence of syncytial knots in <30% of villi, whereas (64.5%) cases showed syncytial knots in >30% of villi.

In our study retroplacental hemorrhage present in 12 cases (44.4%) of mild PET, 13 cases (81.3%) of severe PET and in 6 cases of eclampsia (85.7%), these results come against the results obtained by (Ezeigwe et al., 2018) 100%, 100% and 71.4% for mild, severe and eclampsia cases respectively.

Conclusion:

Our study concluded that, the pathological changes observed in the placentae of patients with hypertensive disorders of pregnancy such as infarctions and calcifications are statistically significant, increase with increase of the severity of hypertension.

References:

- Ahmed M, Daver RG. (2013). Study of placental changes in pregnancy induced hypertension. *Int J Reprod Contracept Obstet Gynecol.*, 2(4):524-7.
- Blackburn S. (2013). Prenatal period and placental physiology. Blackburn S. *Maternal,*

Fetal & Neonatal Physiology: A Clinical Perspective (4th ed.). Washington, Elsevier, 61-114.

Ezeigwe CO, Okafor CI, Eleje GU, Udigwe GO, Anyiam DC. (2018). Placental Peripartum Pathologies in Women with Preeclampsia and Eclampsia. *Obstetrics and Gynecology International*, 2018: 9462938 among symptomatic patients. *BMC infectious Disease*, 19:118-120.

Gude NM, Roberts CT, Kalionis B, King RG. (2004). Growth and function of the normal human placenta. *Thrombosis research*, 114(56): 397-407.

Kambale T, Iqbal B, Ramraje S, Swaimul K, Salve S. (2016). Placental morphology and fetal implications in pregnancies complicated by pregnancy-induced hypertension. *Medical Journal of Dr. DY Patil University*, 9(3): 341.

Krielessi V, Papantoniou N, Papageorgiou I, Chatzipapas I, Manios E, Zakopoulos N et al., (2012). Placental Pathology and Blood Pressure's Level in Women with Hypertensive Disorders in Pregnancy. *Obstetrics and Gynecology International*, 2012: 684083.

Mehare T, Kebede D. (2020). Fetoplacental Weight Relationship in Normal Pregnancy and Pregnancy Complicated by Pregnancy-Induced Hypertension and Abruption of Placenta among Mothers Who Gave Birth in Southern Ethiopia, 2018. *Obstetrics and Gynecology International*, 2020.

Salih S, Omar A. (2017). The relationship between the weight of the placenta and neonatal outcome. *IOSR J Nurs Health Sci.*, 6: 1-8.